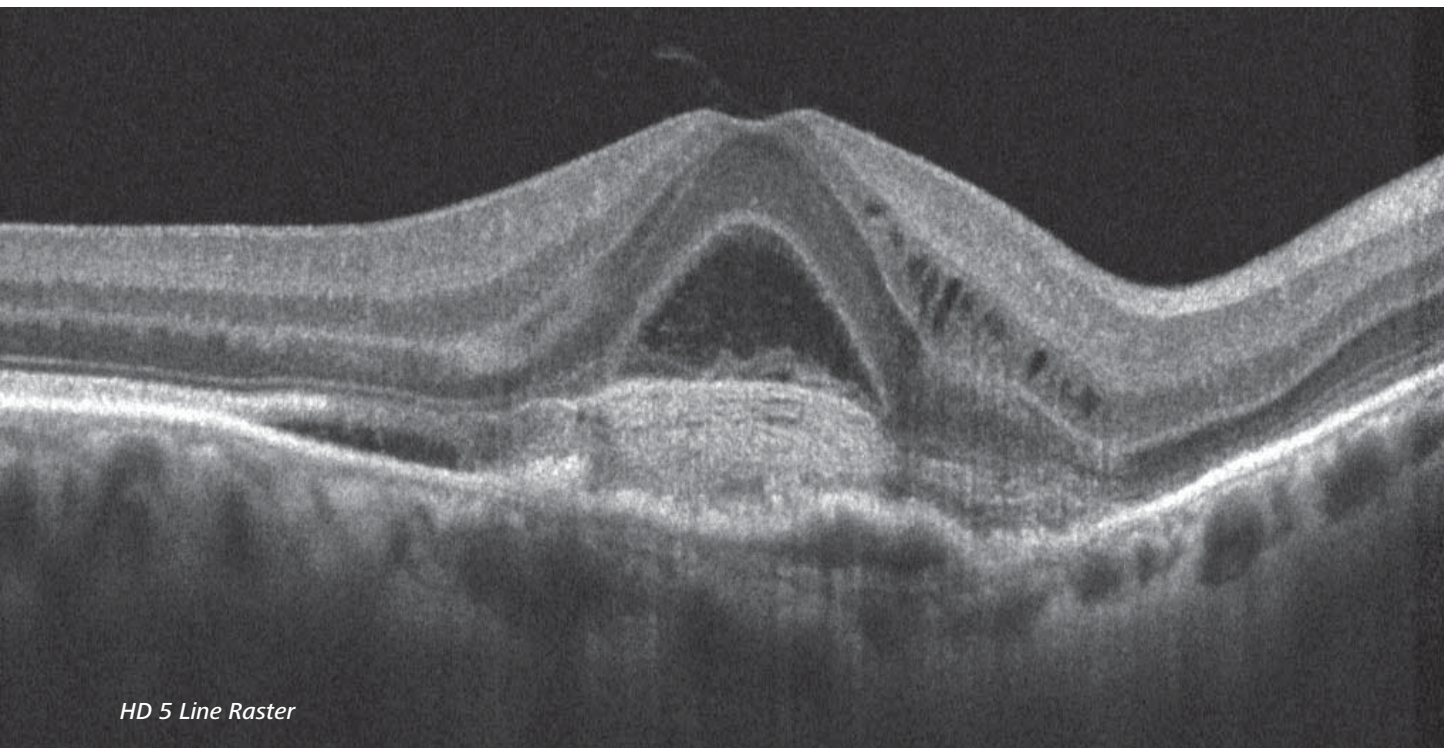
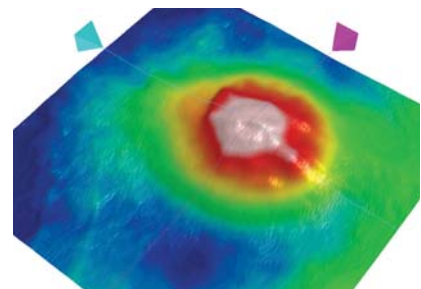


# Image of the Month


featuring Cirrus HD-OCT & VISUCAM<sup>NM/FA</sup>




HD 5 Line Raster



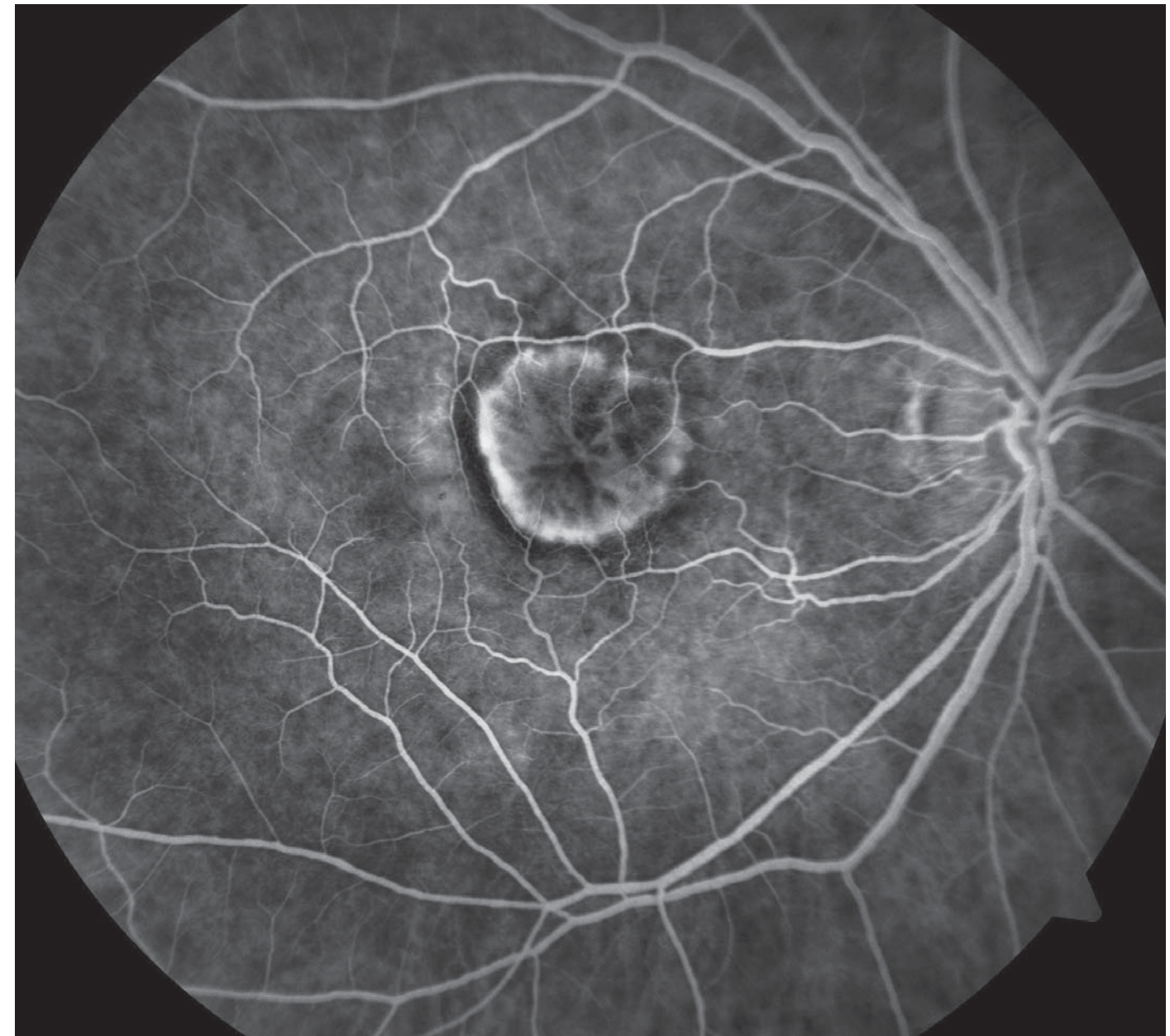Macular Thickness Map



ILM Segmentation Map



RPE Segmentation Map



Early phase (28 seconds) fluorescein angiogram

## Diagnostic Images Courtesy of:

Leslie Brinson, Ophthalmic Technician  
Michael Barondes, MD  
White Eye Associates  
Greenville, NC

## Diagnosis:

Classic (well defined) choroidal neovascularization

## Captured with:

Cirrus<sup>TM</sup> HD-OCT and VISUCAM<sup>NM/FA</sup>

View more ZEISS OCT and Fundus  
images online at [www.retinalphysician.com](http://www.retinalphysician.com)

Carl Zeiss Meditec, Inc. 800-342-9821 [www.meditec.zeiss.com/cirrus](http://www.meditec.zeiss.com/cirrus)



We make it visible.