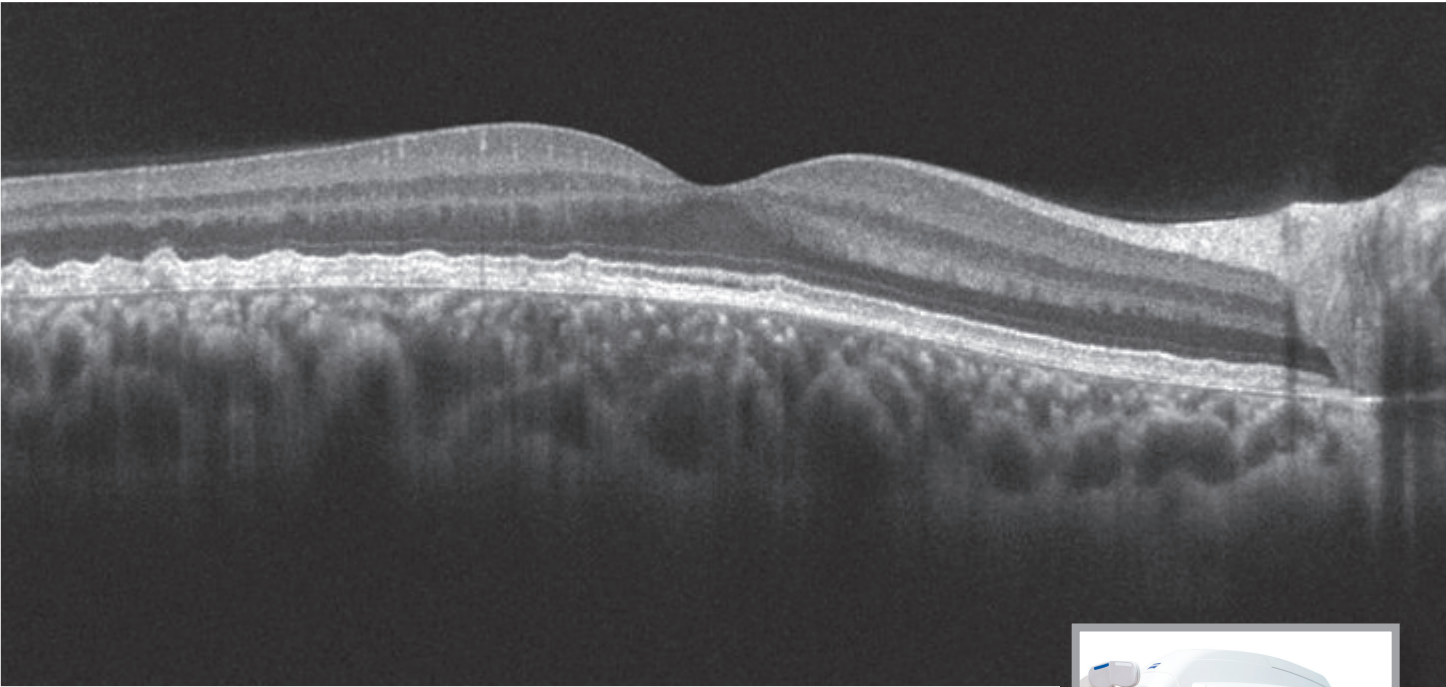


Image of the Month

featuring Cirrus HD-OCT & FF450^{plus}



Diagnostic Images Courtesy of:

Rachel Falk, Director of Photography
Deepa Yoganathan, MD
Director, Retina Service

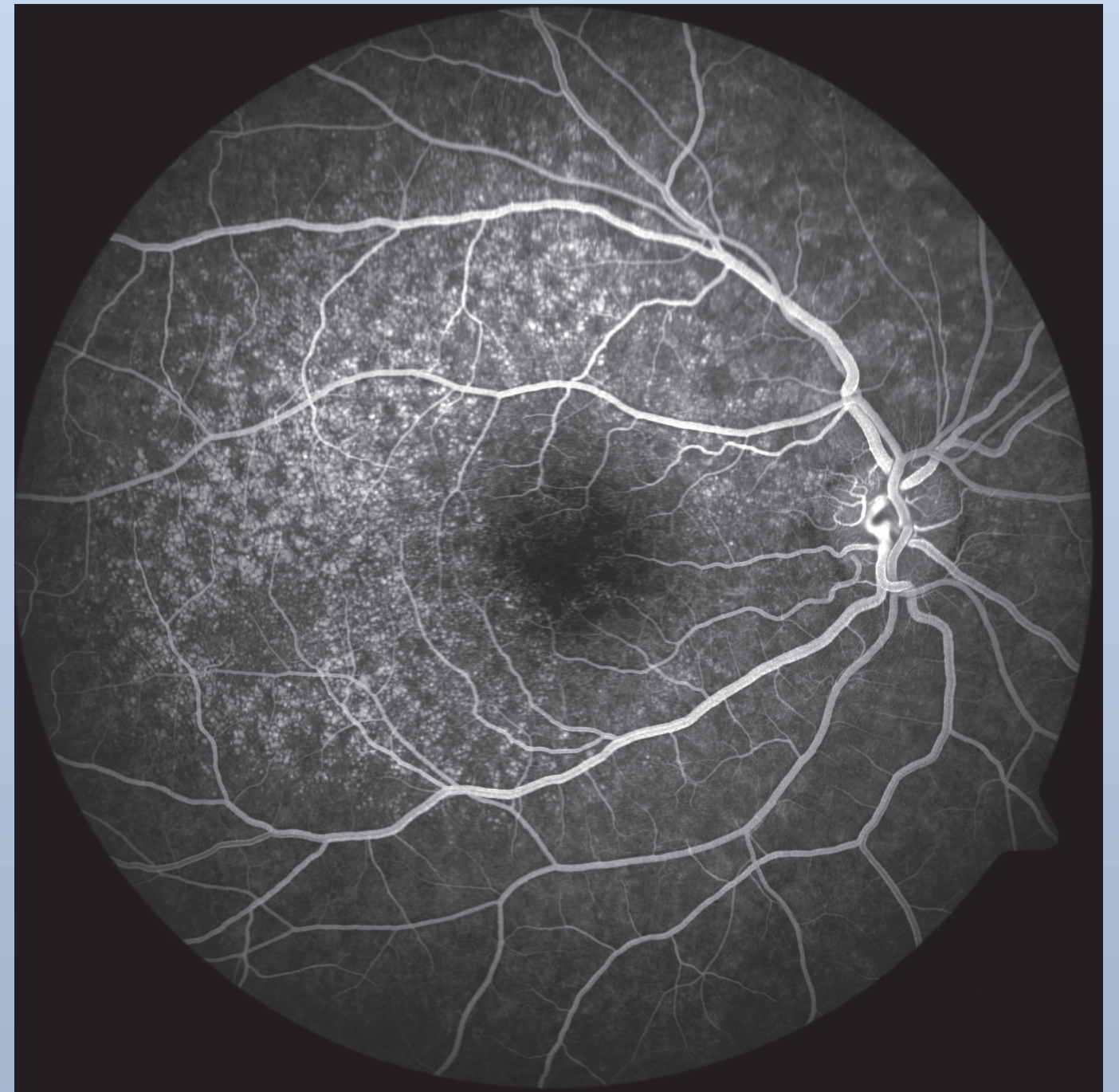
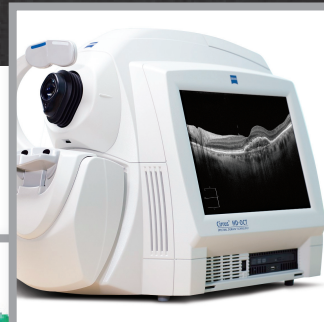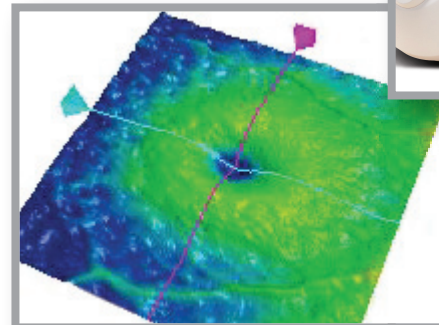
Ross Eye Institute
University at Buffalo
Department of Ophthalmology
Buffalo, NY

Diagnosis: Familial Drusen

Drusen show up as small depressions on the OCT maps, as white nodules on the FA image, and, on the OCT-scan image, as bumps between the RPE and Bruch's membrane.

Captured with:

Cirrus HD-OCT, FF450^{plus} and
VISUPAC Fundus Imaging System 481 with Canon 5D and Pike 421



©2011 Carl Zeiss Meditec, Inc. CIR.3357.0111.

View more ZEISS OCT and Fundus images online at
www.retinalphysician.com/imageofthemonth.asp

Carl Zeiss Meditec, Inc. 800-342-9821 www.meditec.zeiss.com/us

