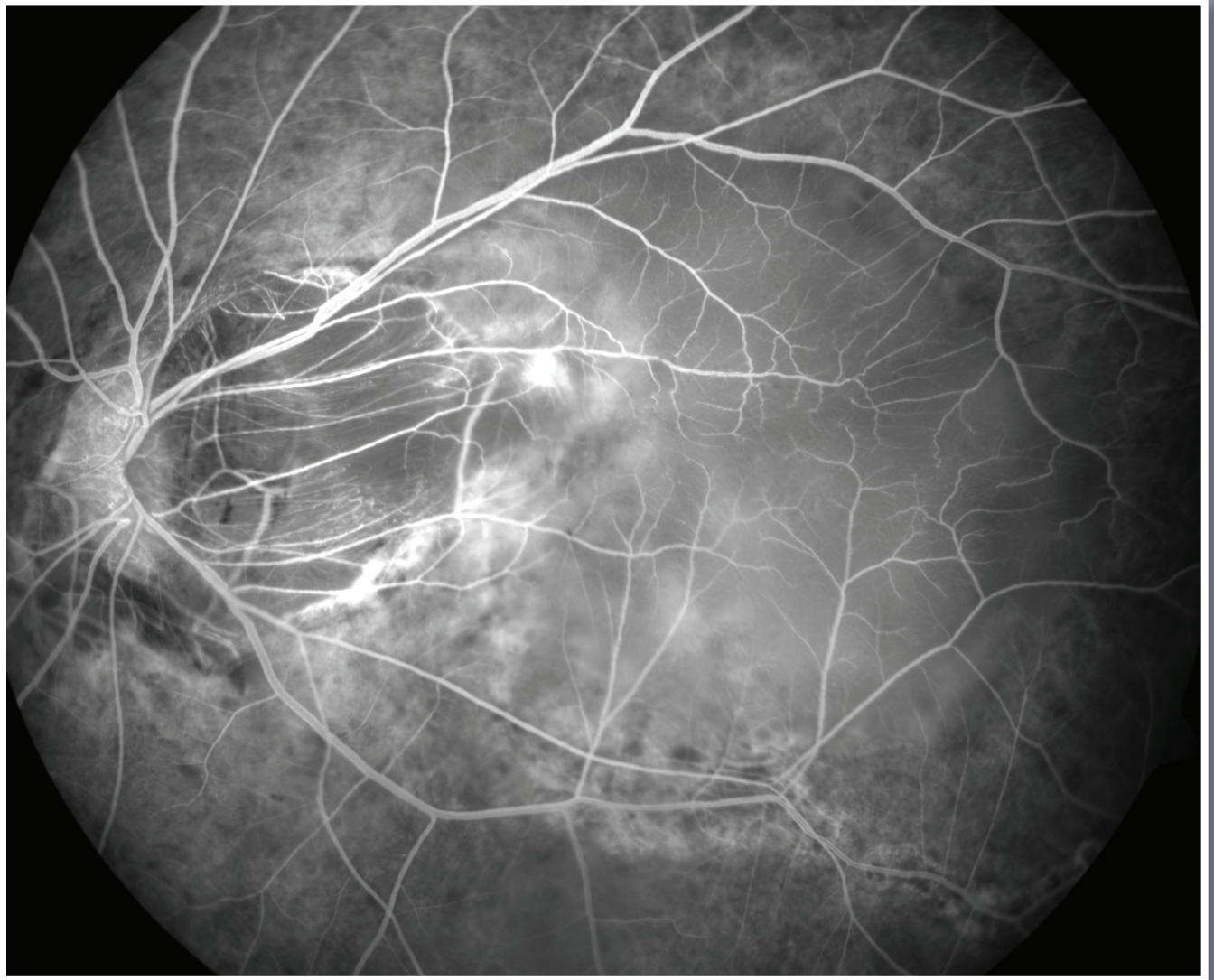


# Photograph of the Month



**Contributed by:** Barbara Kot, Manukau Super Clinic CMDHB, New Zealand

**Image captured with:** FF450<sup>plus</sup> Fundus Camera

**Diagnosis:** Patient presents with high myopia, bilateral pseudophakia, left serous macular retinal detachment overlying posterior staphyloma